

## Patent Foramen Ovale Transcatheter Closure Device Thrombosis

VUYISILE T. NKOMO, MD; PIERRE THEUMA, MD; CALIN V. MANIU, MD; KRISHNASWAMY CHANDRASEKARAN, MD; FLETCHER A. MILLER, MD; HARTZELL V. SCHAFF, MD; GEORGE W. PETTY, MD; AND TODD D. MILLER, MD

The role of patent foramen ovale (PFO) in patients with cryptogenic stroke (stroke of unknown cause) remains controversial, although an association seems likely in younger patients with atrial septal aneurysms and PFO. The mechanism of cryptogenic stroke in these patients is presumed to be paradoxical embolism via right-to-left shunt across the PFO. The available options for treatment include medical therapy with antiplatelet or anticoagulant therapy or closure of the PFO surgically or with use of transcatheter PFO closure devices. We describe 2 cases of bilateral device thrombosis associated with use of a

transcatheter PFO closure device (CardioSEAL). To our knowledge, only 1 other case of thrombosis associated with use of this device has been reported.

*Mayo Clin Proc.* 2001;76:1057-1061

APC-R = activated protein C resistance; ASD = atrial septal defect; DVT = deep venous thrombosis; INR = international normalized ratio; PFO = patent foramen ovale; TEE = transesophageal echocardiography; TIA = transient ischemic attack; TTE = transthoracic echocardiography

The role of patent foramen ovale (PFO) in patients with unexplained (cryptogenic) stroke is not well defined. Management of patients with PFO after an unexplained stroke includes antiplatelet or anticoagulant therapy or closure of the PFO surgically or with use of a transcatheter device. Accumulating data suggest that percutaneous transcatheter device closure of PFO is an effective alternative method to surgical PFO closure.<sup>1-3</sup> We describe 2 cases of an uncommon complication of transcatheter PFO device closure associated with the CardioSEAL device. To our knowledge, only 1 other case of thrombosis associated with use of this device has been reported.<sup>4</sup>

### REPORT OF CASES

#### Case 1

A 55-year-old previously healthy woman had, while gardening, the acute onset of right-hand weakness and numbness lasting approximately 2 hours. There were no accompanying symptoms. She was referred to our institution 13 days after the event for further evaluation of what was presumed to have been a transient ischemic attack (TIA). The patient's medical history was remarkable only for a total abdominal hysterectomy and bilateral salpingo-oophorectomy 4 years earlier for endometriosis, after which she received conjugated estrogen (Premarin), 0.625

mg/d. She was a nonsmoker, her family history was unremarkable, and physical examination findings were normal.

Laboratory data showed normal values for hemoglobin and hematocrit; white blood cell and platelet counts; levels of electrolytes, vitamin B<sub>12</sub>, and folate; prothrombin time and activated partial thromboplastin time; special coagulation testing for the lupus inhibitor; and levels of anti-cardiolipin antibodies, homocysteine, and lipids. Findings on magnetic resonance imaging and angiography of the head were consistent with a recent small infarct in the posterior right centrum semiovale. Bilateral carotid ultrasonography was normal. Transesophageal echocardiography (TEE) showed only a PFO with a large right-to-left shunt on release of Valsalva maneuver. Ultrasonography of the lower extremities was negative for deep venous thrombosis (DVT). Results of spinal fluid evaluation were normal. There was no suspicion of a malignancy.

The patient was presumed to have had a paradoxical embolism and advised to have the PFO closed. Warfarin therapy was prescribed, and the dose of conjugated estrogen was reduced from 0.625 to 0.3 mg/d. She returned home and 1 year later underwent uncomplicated PFO closure with use of a transcatheter device (33-mm CardioSEAL device). A transthoracic echocardiogram (TTE) performed 3 days after the procedure visualized the closure device, and no residual leak was detected. In addition to aspirin, she continued to receive warfarin without heparin with the international normalized ratio (INR) maintained between 2 and 3.

Several weeks after the device closure, the patient began to experience intermittent palpitations, headaches, and photophobia with "fragmented" vision in both visual fields.

From the Division of Cardiovascular Diseases and Internal Medicine (V.T.N., C.V.M., K.C., F.A.M., T.D.M.), Department of Internal Medicine (P.T.), Division of Cardiovascular Surgery (H.V.S.), and Department of Neurology (G.W.P.), Mayo Clinic, Rochester, Minn.

Address reprint requests and correspondence to Todd D. Miller, MD, Division of Cardiovascular Diseases, Mayo Clinic, 200 First St SW, Rochester, MN 55905 (e-mail: miller.todd@mayo.edu).

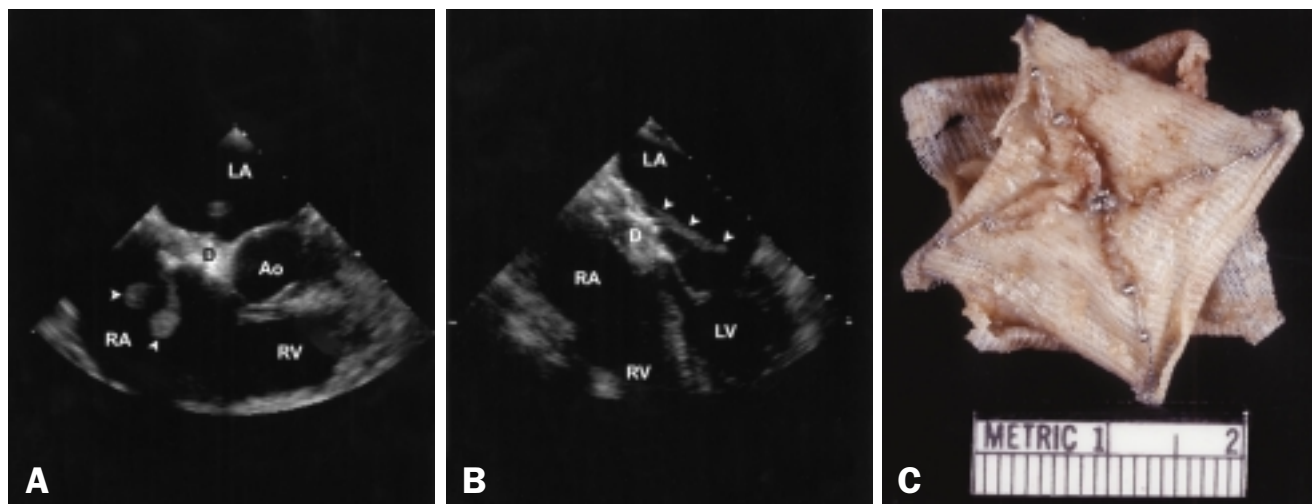


Figure 1. A and B, Transesophageal echocardiographic images showing thrombus (arrowheads) on both sides of the patent foramen ovale closure device. C, Surgically removed CardioSEAL device showing residual thrombus. Ao = aortic valve; D = closure device; LA = left atrium; LV = left ventricle; RA = right atrium; RV = right ventricle.

Computed tomography of the head and TTE were normal. The symptoms continued, and she returned to our institution approximately 3 months after the device closure. A repeat TEE showed a large amount of thrombus attached to both sides of the closure device (Figure 1, A and B). No shunt was present. The INR was 4.5.

Special coagulation studies showed that the patient had factor V R506Q (Leiden) mutation on 1 allele (heterozygous mutant), and the activated protein C resistance (APC-R) ratio was 3.6 (reference range, 2.4-4.0). Other coagulation test results are summarized in Table 1. The device was removed surgically and was found to have adhering to it multiple fragments of fibrovascular tissue and thrombus (Figure 1, C). The PFO was closed with a pericardial patch without complications. Treatment with both warfarin and estrogen was discontinued. The patient had no recurrence of her neurologic symptoms during follow-up of 12 months.

## Case 2

A 48-year-old woman was diagnosed as having suffered a TIA when she presented to her local physicians with transient loss of motor function on the right side of her body that lasted several hours. Computed tomography of her head showed a lesion in the left middle cerebral artery territory consistent with an infarct. Her medical history was unremarkable, and her medications were iron and multivitamin supplements. She had no family history of clotting disorders. Coagulation studies initially showed a positive titer for antiphospholipid antibody (IgM) of 1:8; however, on repeat testing this titer was normal. Protein C and pro-

tein S levels were normal, and no homocysteine levels were reported.

Magnetic resonance angiography of the head and neck vessels showed no notable disease. Transesophageal echocardiography showed a PFO with right-to-left shunting, and the patient was diagnosed as having presumptive paradoxical embolism. No studies were performed to diagnose DVT. The patient subsequently received warfarin, which she did not tolerate well because of heavy menstruation with resultant anemia.

Five months after the TIA, the patient underwent percutaneous closure of the PFO with use of a 28-mm CardioSEAL device without procedural complications. Warfarin treatment was stopped, and she continued to receive aspirin after the procedure. One month after the device closure, the patient experienced transient episodes of blurred vision and 1 episode of transient global amnesia. Follow-up TEE showed thrombus on the left atrial side of the closure device. The patient was hospitalized, given intravenous heparin, and later dismissed having resumed warfarin treatment with an INR of 3.1. A repeat TEE performed 1 month after reinitiation of warfarin showed a persistent thrombus on the device. No data were available regarding the adequacy of her anticoagulation.

The patient was then referred to our institution for surgical removal of the device. Two days prior to arrival, she discontinued warfarin, and the INR on admission was 1.1. A preoperative TEE showed bilateral device thrombosis. The patient then underwent surgical excision of the device and closure of the PFO with a pericardial patch without complications.

## DISCUSSION

According to Thompson and Evans,<sup>5</sup> the term *paradoxical embolism* was introduced in 1885 by Zahn who described a patient diagnosed postmortem as having had uterine thrombi, a PFO with thrombus, and systemic embolization. Since the advent of TTE and TEE, the diagnosis of paradoxical embolism can now be established as symptoms occur. The clinical diagnosis of paradoxical embolism is almost always presumptive and is suspected in patients who have a venous thrombus, a right-to-left shunt, and evidence of arterial embolism. A definite diagnosis of paradoxical embolism is established when a thrombus is seen traversing the shunt.<sup>6,7</sup> The patients described in this article were diagnosed as having presumed paradoxical emboli after presenting with cerebral infarcts of unknown origin manifest as TIAs and were found to have PFO with right-to-left shunt.

Estrogen replacement therapy was not thought to cause the TIA in the patient described in case 1. The relationship between hormone replacement therapy and cerebrovascular disease has been studied extensively.<sup>8</sup> In a pooled analysis of 2000 patients from case-control and cohort studies, no significant association was found between stroke and unopposed estrogen therapy.<sup>9</sup> The Heart and Estrogen/progestin Replacement Study (HERS) showed a pattern of early harm and late benefit from hormone replacement therapy with regard to cerebrovascular accidents; however, the results of that study cannot be applied to the patient described in case 1 since she was taking unopposed estrogen replacement therapy.<sup>10,11</sup> There are no reported data associating stroke and factor V Leiden mutation.

The relationship between estrogen and DVT, on the other hand, is well established.<sup>8,12</sup> Although ultrasonography of the lower extremities in case 1 provided no evidence of DVT, the test was performed when she was first seen at our institution approximately 2 weeks after the TIA. No attempt was made in case 2 to diagnose DVT. Deep venous thromboses are found with variable success in patients suspected of paradoxical embolism, and the prevalence of DVT ranges from 9.5% to 88%, depending on the timing and methods used for diagnosis.<sup>13</sup> The patient in case 1 also carried a factor V mutation on 1 allele. The APC-R ratio of 3.6 may have been artificially normal because of the effect of warfarin. Heterozygous factor V Leiden mutation is a risk factor for venous thrombosis, especially when the APC-R ratio is less than or equal to 2.<sup>14</sup> Carriers of factor V Leiden mutation who use oral contraceptives have a further dramatic increase in risk of venous thrombosis; however, an increase in risk has not been shown for users of hormone replacement therapy who carry the mutation.<sup>15,16</sup> Protein C antigen and activity and free protein S levels were diminished; however, these determinations were performed dur-

Table 1. Coagulation-Related Laboratory Test Results of Case 1\*

Test	Result	Reference range
Prothrombin time (s)	44.6	8.4-12.0
INR	4.5	...
APTT (s)	36	21-33
Thrombin time (s)	16	18-25
Dilute Russell viper venom time		
Screen ratio	1.8	<1.2
Mix ratio	1.0	<1.2
Factor II activity (%)	14	70-130
Factor VII activity (%)	8	65-140
Protein C activity (%)	30	70-130
Protein S (total) (%)	58	50-120
Protein S (free) (%)	38	50-120
APC-R		
Baseline APTT (s)	37	26-38
APTT with APC	133	68-137
APC-R ratio	3.6	2.4-4.0
Anticardiolipin antibodies (IgM and IgG)	Negative	...

\*APC = activated protein C; APC-R = APC resistance; APTT = activated partial thromboplastin time; INR = international normalized ratio.

ing the patient's second referral, while she was taking warfarin with an INR of 4.5, and the results reflect a warfarin effect (Table 1). Following excision of the closure device and pericardial patch closure of the PFO, treatment with both warfarin and estrogen was discontinued in this patient.

No precise guidelines exist for the management of PFO in patients who present with cryptogenic stroke. Studies regarding the relevance of PFO in patients with cryptogenic stroke report conflicting outcomes.<sup>17</sup> Data supporting closure of PFO include a higher risk of stroke recurrence in patients with such a disorder compared with patients without it, especially when it is associated with an atrial septal aneurysm.<sup>18</sup> Current methods of closing PFO involve open heart surgery or transcatheter techniques. Both methods have been shown to be effective<sup>2,3,12,15,19</sup>; however, no prospective randomized trials exist comparing the 2 methods. Medical therapy with antiplatelet or anticoagulant drugs to prevent recurrent neurologic events is an alternative to PFO closure,<sup>20,21</sup> and a multicenter study funded by the National Institutes of Health is under way to assess stroke recurrence in patients randomly assigned to receive anticoagulant or aspirin therapy.

Numerous devices are available for PFO closure,<sup>22-24</sup> and the design and techniques of device implantation have been described previously.<sup>22,23,25-29</sup> Periprocedural complications related to transcatheter atrial septal defect (ASD) or PFO closure include retroperitoneal hematoma, device

embolization, air embolization with or without stroke, atrial perforation, malpositioning of the device with residual shunting, or device arm fracture.<sup>2,3,22,26,29,30</sup> Device thrombosis has been described previously in multiple cases in connection with another ASD occlusion system.<sup>31-33</sup> To our knowledge, only 1 case has been reported that previously described bilateral device thrombosis associated with the CardioSEAL device.<sup>4</sup> In that report, the patient presented with a TIA 6 weeks after implantation of the device and had been maintained on therapeutic levels of warfarin with an INR of 3.5. In addition, no thrombophilic disorder was found.<sup>4</sup> As of March 2000, approximately 2500 CardioSEAL devices have been implanted for a variety of defects, predominantly in the pediatric patient population.<sup>34,35</sup>

The precise reasons for thrombus formation in the 2 cases described herein are unclear. In case 1, the patient continued to receive warfarin following device implantation, and the INR was reportedly maintained between 2 and 3. However, warfarin is known to have a procoagulant effect during initiation,<sup>36</sup> and although unusual, this phenomenon offers one of the potential explanations for device thrombus formation since the patient did not receive concomitant heparin during warfarin reinitiation and was heterozygous for factor V Leiden mutation. Whether a heterozygous state for factor V Leiden mutation per se increases the risk of endovascular prosthesis thrombosis is unknown. In case 2, however, device thrombus formation occurred prior to reinitiation of warfarin while the patient was taking aspirin. No thrombophilic disorder was identified in case 2, although it is unclear whether testing for APC-R was performed. A malignancy was not suspected in either patient based on their clinical history, physical findings, or screening laboratory data.

The CardioSEAL device was recently approved by the US Food and Drug Administration as a Humanitarian Use Device for PFO closure in patients with recurrent cryptogenic stroke due to presumed paradoxical embolism through a PFO and who have failed conventional drug therapy, defined as a therapeutic INR on oral anticoagulation.<sup>37</sup> Known hypercoagulable states contraindicate CardioSEAL device implantation.

## CONCLUSIONS

The reasons for CardioSEAL transcatheter PFO device thrombosis may be related to an underlying hypercoagulable state in 1 patient described herein but are unclear in the other. The cases highlight the need for careful patient evaluation and selection for PFO closure device placement, especially screening for hypercoagulable states. The role of anticoagulation after device placement may need further evaluation.

## REFERENCES

1. Dhillon R, Thanopoulos B, Tsaousis G, Triposkiadis F, Kyriakidis M, Redington A. Transcatheter closure of atrial septal defects in adults with the Amplatzer septal occluder. *Heart*. 1999;82:559-562.
2. Hung J, Landzberg MJ, Jenkins KJ, et al. Closure of patent foramen ovale for paradoxical emboli: intermediate-term risk of recurrent neurological events following transcatheter device placement. *J Am Coll Cardiol*. 2000;35:1311-1316.
3. Windecker S, Wahl A, Chatterjee T, et al. Percutaneous closure of patent foramen ovale in patients with paradoxical embolism: long-term risk of recurrent thromboembolic events. *Circulation*. 2000;101:893-898.
4. Stangl V, Stangl K, Bohm J, Felix SB. Images in cardiothoracic surgery: thrombus formation after catheter closure of an atrial septal defect with a clamshell device. *Ann Thorac Surg*. 2000;69:1956.
5. Thompson T, Evans W. Paradoxical embolism. *Q J Med*. 1930;23:135-150.
6. Gleysteen JJ, Silver D. Paradoxical arterial embolism: collective review. *Am Surg*. 1970;36:47-54.
7. Meister SG, Grossman W, Dexter L, Dalen JE. Paradoxical embolism: diagnosis during life. *Am J Med*. 1972;53:292-298.
8. Tavani A, La Vecchia C. The adverse effects of hormone replacement therapy. *Drugs Aging*. 1999;14:347-357.
9. Grady D, Rubin SM, Petitti DB, et al. Hormone therapy to prevent disease and prolong life in postmenopausal women. *Ann Intern Med*. 1992;117:1016-1037.
10. Herrington DM. The HERS trial results: paradigms lost? Heart and Estrogen/progestin Replacement Study. *Ann Intern Med*. 1999;131:463-466.
11. Hulley S, Grady D, Bush T, et al, Heart and Estrogen/progestin Replacement Study (HERS) Research Group. Randomized trial of estrogen plus progestin for secondary prevention of coronary heart disease in postmenopausal women. *JAMA*. 1998;280:605-613.
12. Daly E, Vessey MP, Hawkins MM, Carson JL, Gough P, Marsh S. Risk of venous thromboembolism in users of hormone replacement therapy. *Lancet*. 1996;348:977-980.
13. Lethen H, Flachskampf FA, Schneider R, et al. Frequency of deep vein thrombosis in patients with patent foramen ovale and ischemic stroke or transient ischemic attack. *Am J Cardiol*. 1997;80:1066-1069.
14. Svensson PJ, Dahlback B. Resistance to activated protein C as a basis for venous thrombosis. *N Engl J Med*. 1994;330:517-522.
15. Vandenbroucke JP, Koster T, Briet E, Reitsma PH, Bertina RM, Rosendaal FR. Increased risk of venous thrombosis in oral-contraceptive users who are carriers of factor V Leiden mutation. *Lancet*. 1994;344:1453-1457.
16. Waselenko JK, Nace MC, Alving B. Women with thrombophilia: assessing the risks for thrombosis with oral contraceptives or hormone replacement therapy. *Semin Thromb Hemost*. 1998;24(suppl 1):33-39.
17. Petty GW, Khandheria BK, Chu CP, Sicks JD, Whisnant JP. Patent foramen ovale in patients with cerebral infarction: a transesophageal echocardiographic study. *Arch Neurol*. 1997;54:819-822.
18. Hanna JP, Sun JP, Furlan AJ, Stewart WJ, Sila CA, Tan M. Patent foramen ovale and brain infarct: echocardiographic predictors, recurrence, and prevention. *Stroke*. 1994;25:782-786.
19. Homma S, Di Tullio MR, Sacco RL, Sciacca RR, Smith C, Mohr JP. Surgical closure of patent foramen ovale in cryptogenic stroke patients. *Stroke*. 1997;28:2376-2381.
20. Comess KA, DeRook FA, Beach KW, Lytle NJ, Golby AJ, Albers GW. Transesophageal echocardiography and carotid ultrasound in patients with cerebral ischemia: prevalence of findings and recurrent stroke risk. *J Am Coll Cardiol*. 1994;23:1598-1603.
21. Mas JL, Zuber M, French Study Group on Patent Foramen Ovale and Atrial Septal Aneurysm. Recurrent cerebrovascular events in patients with patent foramen ovale, atrial septal aneurysm, or both and cryptogenic stroke or transient ischemic attack. *Am Heart J*. 1995;130:1083-1088.

22. Walsh KP, Maadi IM. The Amplatzer septal occluder. *Cardiol Young*. 2000;10:493-501.
23. Latson LA. Per-catheter ASD closure. *Pediatr Cardiol*. 1998;19:86-93.
24. Butera G, Bini MR, Chessa M, Bedogni F, Onofri M, Carminati M. Transcatheter closure of patent foramen ovale in patients with cryptogenic stroke. *Ital Heart J*. 2001;2:115-118.
25. Lock JE, Rome JJ, Davis R, et al. Transcatheter closure of atrial septal defects: experimental studies. *Circulation*. 1989;79:1091-1099.
26. Bridges ND, Hellenbrand W, Latson L, Filiano J, Newburger JW, Lock JE. Transcatheter closure of patent foramen ovale after presumed paradoxical embolism. *Circulation*. 1992;86:1902-1908.
27. Hausdorf G, Schneider M, Franzbach B, Kampmann C, Kargus K, Goeldner B. Transcatheter closure of secundum atrial septal defects with the atrial septal defect occlusion system (ASDOS): initial experience in children. *Heart*. 1996;75:83-88.
28. Ende DJ, Chopra PS, Rao PS. Transcatheter closure of atrial septal defect or patent foramen ovale with the buttoned device for prevention of recurrence of paradoxical embolism. *Am J Cardiol*. 1996;78:233-236.
29. Pedra CA, McLaughlin P, Benson LN. The role of CardioSEAL and Starflex devices in atrial defect occlusion. *Curr Interv Cardiol Rep*. 2000;2:274-282.
30. Prieto LR, Foreman CK, Cheatham JP, Latson LA. Intermediate-term outcome of transcatheter secundum atrial septal defect closure using the Bard Clamshell Septal Umbrella. *Am J Cardiol*. 1996;78:1310-1312.
31. Sievert H, Babic UU, Hausdorf G, et al. Transcatheter closure of atrial septal defect and patent foramen ovale with ASDOS device (a multi-institutional European trial). *Am J Cardiol*. 1998;82:1405-1413.
32. Bohm J, Bittigau K, Kohler F, Baumann G, Konertz W. Surgical removal of atrial septal defect occlusion system-devices. *Eur J Cardiothorac Surg*. 1997;12:869-872.
33. Gastmann O, Werner GS, Babic UU, Figulla HR. Thrombus formation on transcatheter ASD occluder device in a patient with coagulation factor XII deficiency. *Cathet Cardiovasc Diagn*. 1998;43:81-83.
34. NMT Medical, Inc. Cardiac implants: clinical results with CardioSEAL. Available at: [www.nmtmedical.com/products/ci/results.htm](http://www.nmtmedical.com/products/ci/results.htm). Accessibility verified July 20, 2001.
35. Carminati M, Giusti S, Hausdorf G, et al. A European multicentric experience using the CardioSEAL and Starflex double umbrella devices to close interatrial communications holes within the oval fossa. *Cardiol Young*. 2000;10:519-526.
36. Conway EM, Bauer KA, Barzegar S, Rosenberg RD. Suppression of hemostatic system activation by oral anticoagulants in the blood of patients with thrombotic diatheses. *J Clin Invest*. 1987;80:1535-1544.
37. Food and Drug Administration. CardioSEAL septal occlusion system: summary of safety and probable benefit. Available at: [www.fda.gov/cdrh/pdf/h990011b.pdf](http://www.fda.gov/cdrh/pdf/h990011b.pdf). Accessibility verified July 20, 2001.

