

Relation between Directly Detected Patent Foramen Ovale and Ischemic Brain Lesions in Sport Divers

Markus Schwerzmann, MD; Christian Seiler, MD; Ernst Lipp, MD; Raphael Guzman, MD; Karl O. Lövblad, MD; Martin Kraus, MD; and Nils Kucher, MD

Background: In divers, the significance of a patent foramen ovale and its potential relation to paradoxical gas emboli remain uncertain.

Objective: To assess the prevalence of symptoms of decompression illness and ischemic brain lesions in divers with regard to the presence of a patent foramen ovale.

Design: Retrospective cohort study.

Setting: University hospital and three diving clubs in Switzerland.

Participants: 52 sport divers and 52 nondiving controls.

Measurements: Prevalence of self-reported decompression events, patent foramen ovale on contrast transesophageal echo-

cardiography, and ischemic brain lesions on magnetic resonance imaging.

Results: The risk for decompression illness events was 4.5-fold greater in divers with patent foramen ovale than in divers without patent foramen ovale (risk ratio, 4.5 [95% CI, 1.2 to 18.0]; $P = 0.03$). Among divers, 1.23 ± 2.0 and 0.64 ± 1.22 ischemic brain lesions per person (mean \pm SD) were detected in those with and those without patent foramen ovale, respectively. Among controls, 0.22 ± 0.44 and 0.12 ± 0.63 lesion per person were detected ($P < 0.001$ for all groups).

Conclusions: Regardless of whether a diver has a patent foramen ovale, diving is associated with ischemic brain lesions.

Ann Intern Med. 2001;134:21-24.

www.annals.org

For author affiliations, current addresses, and contributions, see end of text.

Scuba diving involves a risk for neurologic injuries caused by decompression sickness, arterial gas embolism, anoxia, and the toxic effects of high partial pressure of breathing gases (1). Most neuroimaging studies for detection of ischemic brain lesions have been performed in divers with acute decompression-related injuries of the central nervous system (2, 3). However, as a recent study has shown (4), most divers may be neurologically asymptomatic despite an increased prevalence of brain lesions compared with nondiving controls. Reul and colleagues (4) found 80% of all brain lesions in a subgroup of 27% of divers, possibly those with patent foramen ovale who had paradoxical arterial gas embolism during decompression (4). Knauth and coworkers (5) used transcranial Doppler ultrasonography to detect a right-to-left shunt in 87 sport divers; they reported that multiple brain lesions on magnetic resonance imaging (MRI) occurred exclusively in those with a large right-to-left shunt, which was presumed to be a patent foramen ovale (5). Detection of intravenously injected echocontrast bubbles in the cerebral vasculature is not specific for a patent foramen ovale; moreover, compared with transesophageal echocardiography, detection of these bubbles has been found to be only 68% sensitive in detecting a patent foramen ovale (6).

We used MRI and transesophageal echocardiography to determine the prevalence of decompression illness symptoms and ischemic brain lesions in relation to a patent foramen ovale in sport divers.

METHODS

Participants

Cranial MRI and contrast transesophageal echocardiography were performed in 52 sport divers and 52 healthy nondiving controls. Divers at three diving clubs from three different areas in Switzerland were informed about our study. We enrolled the first 57 divers who responded, had 200 or more dives using compressed air, and adhered to decompression tables. Claustrophobia prohibited 5 divers from having cranial MRI. For the control group, healthy nondiving persons from the hospital staff were asked to participate in the study.

The study was approved by the institutional ethics committee, and participants gave informed consent.

Health Status, Diving Habits, and Accidents

Before examining the participants, we used a questionnaire to ask them about their medical and diving history. Diving history included average diving depth; number of dives to a depth of 40 m or greater; and

Table. Participant Characteristics*

Characteristic	Divers		Nondiving Controls		P Value
	With Patent Foramen Ovale (n = 13)	Without Patent Foramen Ovale (n = 39)	With Patent Foramen Ovale (n = 9)	Without Patent Foramen Ovale (n = 43)	
Age, y	38 ± 10†	35 ± 8†	36 ± 6	31 ± 7	0.02
Men, %	10 (77)	30 (77)	8 (89)	30 (70)	>0.2
Blood pressure, mm Hg	120/72	117/66	115/70	118/68	>0.2
Daily alcohol use, n (%)	2 (15)	4 (10)	2 (22)	1 (2)	0.15
Smoking, pack-years	9 ± 12	6 ± 9	3 ± 4	1 ± 3	0.07
Hypertension, n (%)	2 (15)	0	0	0	>0.2
Migraine, n (%)	2 (15)	1 (3)	0	0	>0.2
No medication, n (%)	10 (77)	39 (100)	9 (100)	43 (100)	>0.2
Dives, n	721 ± 519	758 ± 1616	–	–	>0.2
Diving depth, m	26 ± 7	25 ± 7	–	–	>0.2
Dives deeper than 40 m, n	59 ± 48	75 ± 115	–	–	>0.2

* Values with the plus/minus sign are the mean ± SD.

† $P < 0.05$ versus controls without patent foramen ovale.

occurrence of symptoms of decompression illness, which included symptoms of decompression sickness and of arterial gas embolism (7). Signs of spinal decompression illness were limb weakness, cutaneous sensory level, and impaired bowel or bladder control; signs of cerebral decompression illness were blurred vision, dysarthria, hemiplegia, or loss of consciousness. Onset of symptoms in arterial gas embolism is much faster than in decompression sickness, often occurring within minutes after surfacing or during decompression (7).

Diagnostic Imaging

Magnetic resonance imaging was done by using a 1.5-T Magnetom Vision system (Siemens, Erlangen, Germany) equipped with a head coil. The imaging protocol included T1-weighted, T2-weighted, and proton density-weighted imaging. Images were reviewed independently by two neuroradiologists blinded to study group and to whether a patent foramen ovale was present. A lesion was counted if it was hyperintense on proton density-weighted and T2-weighted images.

After MRI, transesophageal echocardiography was done by using an Acuson Sequoia C256 system (Sequoia, Mountain View, California) equipped with a multiplane, 3.5- to 7-MHz probe. Echocontrast tests (Physiogel [Braun, Emmenbruecke, Switzerland] with air in a 9:1 ratio) were performed in the transversal and longitudinal image plane by injection of 2 mL of contrast into an antecubital vein. Direct shunting of contrast bubbles into the left atrium through the foramen ovale was detected by applying the Valsalva maneuver.

Statistical Analysis

Assuming a non-normal distribution of data, we compared continuous data by using the Wilcoxon rank-sum test or the Kruskal–Wallis test. Adjustment for multiple testing was done by using the Bonferroni method. Between-group comparison of categorical data was done by using logistic regression for dichotomous outcomes and Poisson regression for count data. Values are expressed as the mean (\pm SD) or as odds or incidence ratios with 95% CIs. A P value less than 0.05 was considered statistically significant.

RESULTS

Thirteen of 52 divers (25%) and 9 of 52 controls (17%) had a patent foramen ovale (odds ratio, 1.47 [95% CI, 0.78 to 2.23]; $P > 0.2$). Divers were older and smoked more than controls (Table). Diving habits were similar among the two groups of divers (Table).

Spinal or cerebral symptoms of decompression sickness occurred in 4 of 13 divers with and 4 of 39 divers without a patent foramen ovale (odds ratio, 3.0 [CI, 1.4 to 7.2]; $P = 0.03$) (Figure). Arterial gas embolism occurred in 4 of 13 divers with and 2 of 39 divers without patent foramen ovale (odds ratio, 6.0 [CI, 2.4 to 12.6]; $P = 0.007$) (Figure). In a logistic regression model, patent foramen ovale increased the risk for decompression illness events in divers by 4.5-fold (risk ratio, 4.5 [CI, 1.2 to 18.0]; $P = 0.03$) during all dives.

There were 41 ischemic brain lesions in 19 divers and 7 lesions in 6 controls (odds ratio, 5.8 [CI, 3.7 to 9.4]; $P = 0.003$). Among divers with and those without

patent foramen ovale, 16 and 25 ischemic lesions were detected, respectively (1.23 ± 2.0 and 0.64 ± 1.22 ischemic brain lesions per person); in contrast, 2 and 5 ischemic lesions were detected in controls with and those without patent foramen ovale (0.22 ± 0.44 and 0.12 ± 0.63 lesion per person) ($P < 0.001$ for all groups) (Figure). In a Poisson regression model, diving increased the incidence of 1 or more ischemic brain lesions by fivefold (incidence ratio, 5.2 [CI, 1.2 to 22]; $P = 0.03$). Almost twice as many ischemic brain lesions were seen in divers with patent foramen ovale than in those without patent foramen ovale (incidence ratio, 1.8 [CI, 0.94 to 3.35]; $P = 0.07$) (Figure).

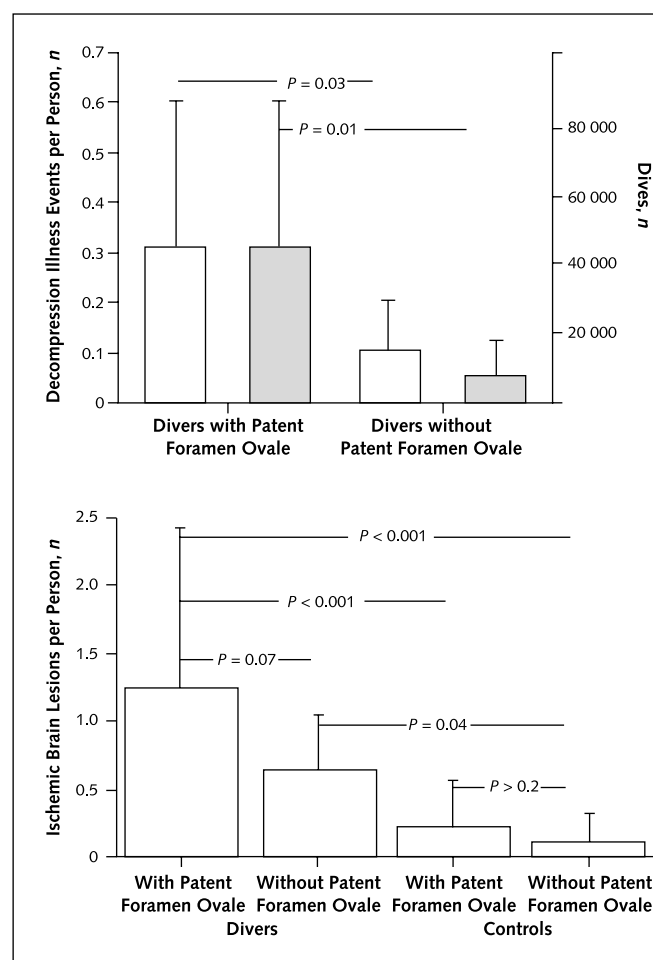
DISCUSSION

Neurologic injuries related to decompression illness in divers are due to regional gas nucleation that predominantly occurs in fat-containing tissue (decompression sickness) or invasion of gas into the systemic circulation (arterial gas embolism). Both of these conditions may manifest as ischemic lesions in the central nervous system. In our study, 14 decompression illness events took place in 9 of 52 divers (17%). Of these 9 divers, only 2 had one or more ischemic brain lesions on MRI. Therefore, the presence of ischemic brain lesions does not appear to correlate with neurofunctional manifestations of decompression events; instead, it may primarily depend on the global burden of decompression dives.

The frequency of asymptomatic divers with ischemic brain lesions in our study (19 of 43 [44%]) is similar to that in a study by Reul and colleagues (27 of 52 [52%]) (4). That study and a neuroimaging magnetic resonance study in professional divers (8) appear to be the only published controlled trials to date, and their findings were discordant: Reul and colleagues (4) observed an increased number of ischemic brain lesions compared with nondiving controls, whereas Todnem and associates (8) found a similar number of lesions. This discrepancy may be related to variable frequency in the occurrence of a patent foramen ovale, a condition that has been implicated as a factor in the pathophysiology of diving-related brain damage but never investigated in a controlled fashion together with cerebral MRI (5, 9, 10).

In 1986, Wilmshurst and associates (11) suggested that atrial septal defect and patent foramen ovale may be relevant to paradoxical gas embolism among scuba divers (11). Subsequent studies did not include a con-

Figure. Decompression sickness events and ischemic brain lesions in divers and nondivers.



Top. Average number of decompression sickness events (white bars) and arterial gas emboli (gray bars) and the frequency of these events per 10 000 dives. Bottom. Average number of ischemic brain lesions seen on magnetic resonance imaging.

trol group, cerebral neuroimaging, or transesophageal echocardiography for diagnosis of patent foramen ovale. In a study by Germonpre and colleagues (12), a control group of asymptomatic divers was compared with 37 matched divers who had decompression sickness, but neuroimaging was not performed. The prevalence of patent foramen ovale was 60% among divers with decompression sickness and 36% among those without decompression sickness ($P = 0.06$). However, these data and those of Knauth and coworkers (5) do not indicate whether it is diving or the presence of a patent foramen ovale plus diving that causes brain damage. We found

that presence of a patent foramen ovale rather than diving itself is responsible for a higher prevalence of clinical events. However, the absolute frequency of decompression sickness or arterial gas embolism is quite low, and from an epidemiologic point of view, clinical problems related to diving in persons with patent foramen ovale are not an important issue.

Because half of divers with ischemic brain lesions are asymptomatic even after almost 1000 dives, the risk of diving is related to the potential for neurologic long-term effects of these lesions. In addition, patent foramen ovale in divers was associated with a higher prevalence of ischemic brain lesions.

Our study has some limitations. Selection bias of divers with more frequent events of decompression illness events could have occurred, thus creating a tendency toward more brain lesions in divers. However, this is unlikely because the prevalence of patent foramen ovale in divers and controls did not differ significantly and the frequency of patent foramen ovale in divers was lower than that observed in the general population (13).

Controls were selected from the hospital staff rather than the general population. This may have accounted for the statistical difference in age between all groups and the trend toward more smokers among divers. Because of the small number of outcome events, we did not adjust for these potential confounders or effect modifiers.

In conclusion, diving itself, more than diving in the presence of a patent foramen ovale, is associated with the presence of ischemic brain lesions compared with persons who do not dive. However, divers with a patent foramen ovale have a 4.5-fold increase in decompression illness events and two times more ischemic brain lesions than divers without patent foramen ovale.

From Swiss Cardiovascular Center Bern and University Hospital, Bern, Switzerland.

Acknowledgments: The authors thank Aija Kinnunen, Marika Kabok, and Liza Needergerd for assistance with transesophageal echocardiography.

Requests for Single Reprints: Christian Seiler, MD, Swiss Cardiovascular Center Bern, Department of Cardiology, University Hospital, 3010 Bern, Switzerland; e-mail, christian.seiler.cardio@insel.ch.

Current Author Addresses: Drs. Schwerzmann, Seiler, Lipp, and Kucher: Swiss Cardiovascular Center Bern, Cardiology, University Hospital, 3010 Bern, Switzerland.
Drs. Guzman and Lövblad: Department of Neuroradiology, University Hospital Bern, 3010 Bern, Switzerland.

Dr. Kraus: Schweizerische Gesellschaft für Unterwasser- und Hyperbarmedizin, Rathausstrasse 11, 8570 Weinfelden, Switzerland.

Author Contributions: Conception and design: M. Schwerzmann, C. Seiler.

Analysis and interpretation of the data: M. Schwerzmann, C. Seiler, K. Lövblad.

Drafting of the article: M. Schwerzmann, C. Seiler.

Critical revision of the article for important intellectual content: M. Kraus.

Final approval of the article: C. Seiler.

Provision of study materials or patients: M. Schwerzmann, C. Seiler, E. Lipp, R. Guzman, N. Kucher.

Statistical expertise: M. Schwerzmann, C. Seiler.

Administrative, technical, or logistic support: M. Schwerzmann, C. Seiler, E. Lipp, R. Guzman, K. Lövblad, M. Kraus, N. Kucher.

Collection and assembly of data: M. Schwerzmann, C. Seiler, E. Lipp, K. Lövblad.

References

1. Wilmshurst P. Brain damage in divers [Editorial]. *BMJ*. 1997;314:689-90. [PMID: 0009116536]
2. Rinck PA, Svihus R, de Francisco P. MR imaging of the central nervous system in divers. *J Magn Reson Imaging*. 1991;1:293-9. [PMID: 0001802142]
3. Warren LP Jr, Djang WT, Moon RE, Camporesi EM, Sallee DS, Anthony DC, et al. Neuroimaging of scuba diving injuries to the CNS. *AJR Am J Roentgenol*. 1988;151:1003-8. [PMID: 0003262997]
4. Reul J, Weis J, Jung A, Willmes K, Thron A. Central nervous system lesions and cervical disc herniations in amateur divers. *Lancet*. 1995;345:1403-5. [PMID: 0007760611]
5. Knauth M, Ries S, Pohimann S, Kerby T, Forsting M, Daffertshofer M, et al. Cohort study of multiple brain lesions in sport divers: role of a patent foramen ovale. *BMJ*. 1997;314:701-5. [PMID: 0009116544]
6. Di Tullio M, Sacco RL, Venketasubramanian N, Sherman D, Mohr JP, Homma S. Comparison of diagnostic techniques for the detection of a patent foramen ovale in stroke patients. *Stroke*. 1993;24:1020-4. [PMID: 0008322376]
7. Elliott DH, Moon RE. Manifestations of the decompression disorders. In: Bennett PB, Elliott DH, eds. *The Physiology and Medicine of Diving*. Philadelphia: Saunders; 1993:481.
8. Todnem K, Nyland H, Skeidsvoll H, Svihus R, Rinck P, Kambestad BK, et al. Neurological long term consequences of deep diving. *Br J Ind Med*. 1991;48:258-66. [PMID: 0002025592]
9. Wilmshurst P. Right-to-left shunt and neurological decompression sickness in divers [Letter]. *Lancet*. 1990;336:1071-2. [PMID: 0001977048]
10. Moon RE, Camporesi EM, Kisslo JA. Patent foramen ovale and decompression sickness in divers. *Lancet*. 1989;1:513-4. [PMID: 0002564057]
11. Wilmshurst PT, Ellis BG, Jenkins BS. Paradoxical gas embolism in a scuba diver with an atrial septal defect. *Br Med J (Clin Res Ed)*. 1986;293:1277. [PMID: 0003096463]
12. Germonpre P, Dendale P, Unger P, Balestra C. Patent foramen ovale and decompression sickness in sports divers. *J Appl Physiol*. 1998;84:1622-6. [PMID: 0009572808]
13. Hagen PT, Scholz DG, Edwards WD. Incidence and size of patent foramen ovale during the first 10 decades of life: an autopsy study of 965 normal hearts. *Mayo Clin Proc*. 1984;59:17-20. [PMID: 0006694427]